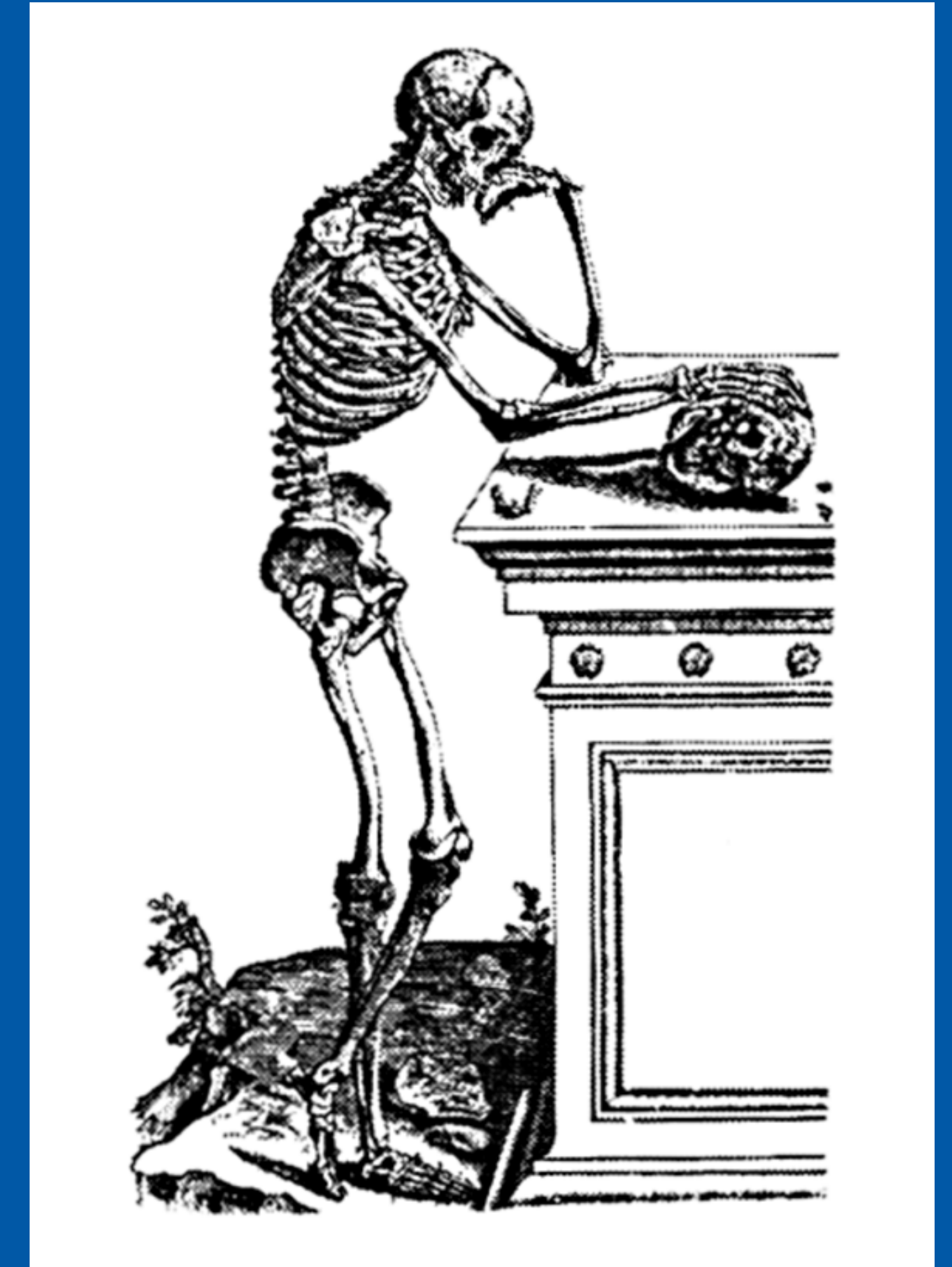


42nd Annual Meeting, Scottsdale, Arizona
Society of Skeletal Radiology
March 10-13, 2019



CASE OF THE DAY: SUNDAY

 #SSRBONE19COD2

David Gimarc, MD; Michael Tuite, MD; Jason Stephenson, MD
University of Wisconsin, Madison, WI

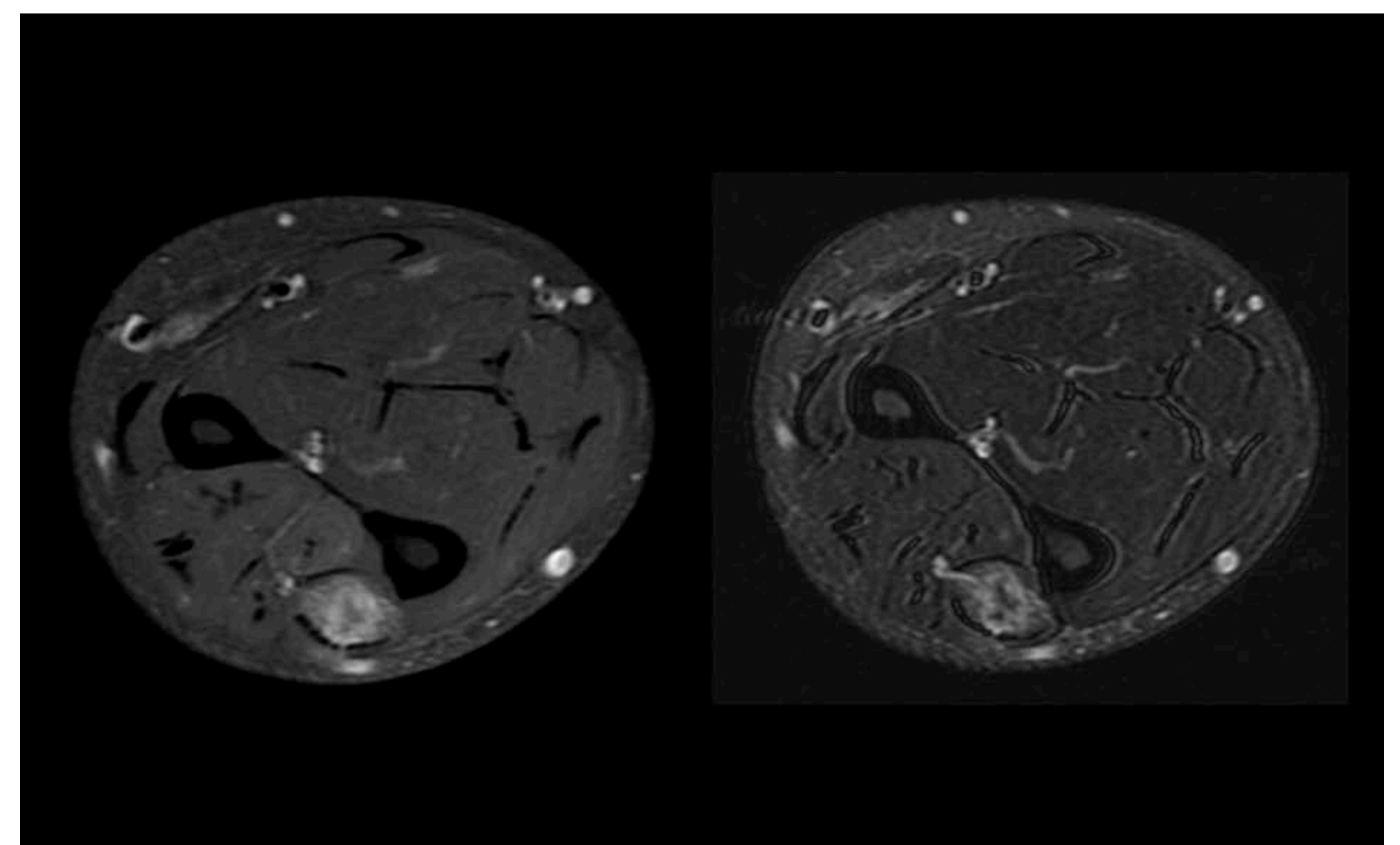
HISTORY

- 49-year-old man
- Recently noticed multiple subcutaneous lumps on right forearm, right shoulder, and left rib
- Painless

DIAGNOSIS

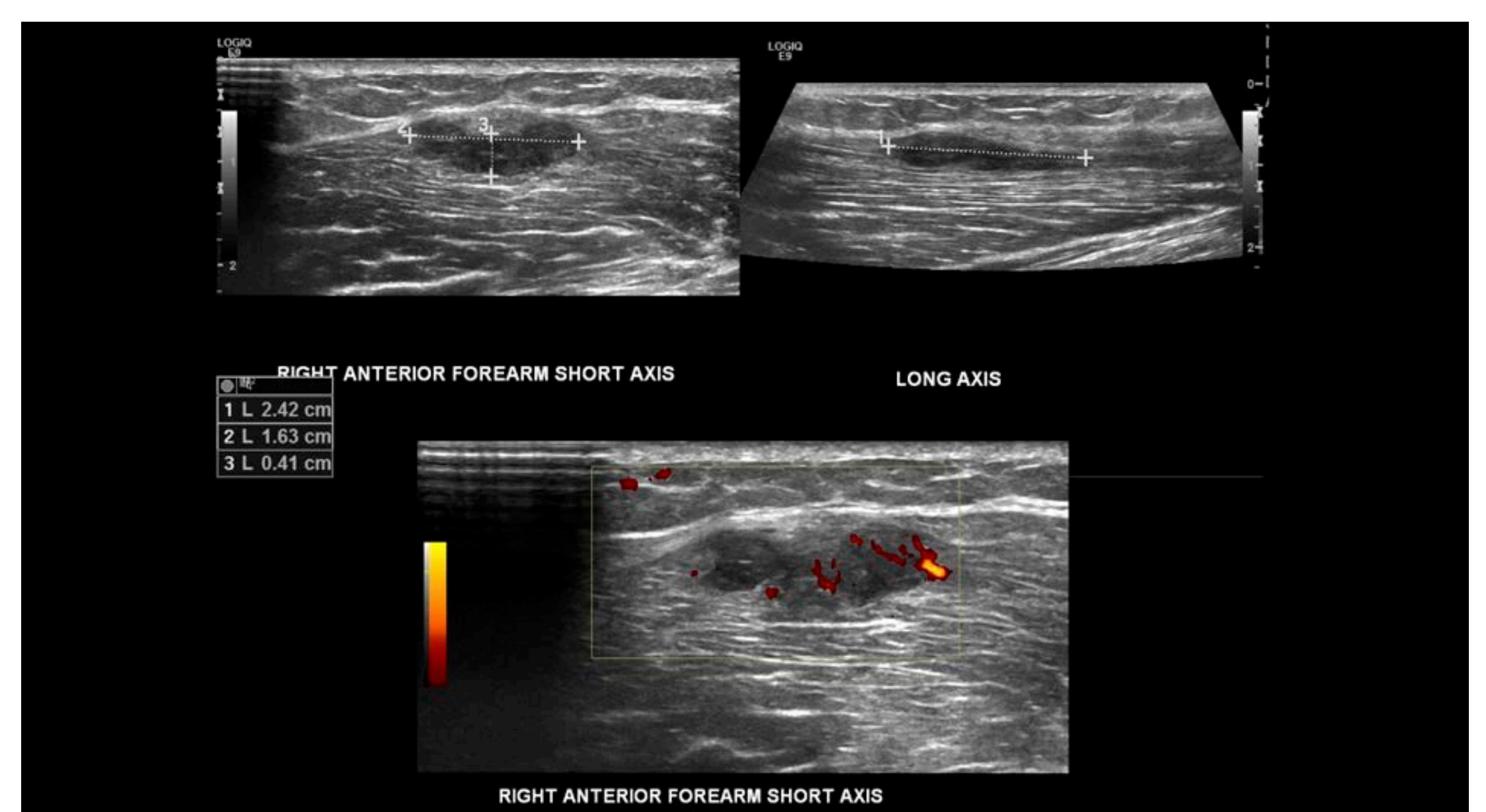
Intramuscular Sarcoidosis

- Sarcoidosis can involve any organ
- Accumulation of T-lymphocytes and phagocytes leads to the development of non-caseating granulomas
- Extra-pulmonary sarcoidosis is present in approximately 30% of patients, almost always present in combination with pulmonary symptoms
- MSK manifestations can involve joints, bone, skin, and muscle
- Symptomatic myopathy present in up to 5% of patients, though asymptomatic myopathy is hypothesized present in 25-75%



Axial T1 FS +Gd

Axial T2 FS



RIGHT ANTERIOR FOREARM SHORT AXIS

