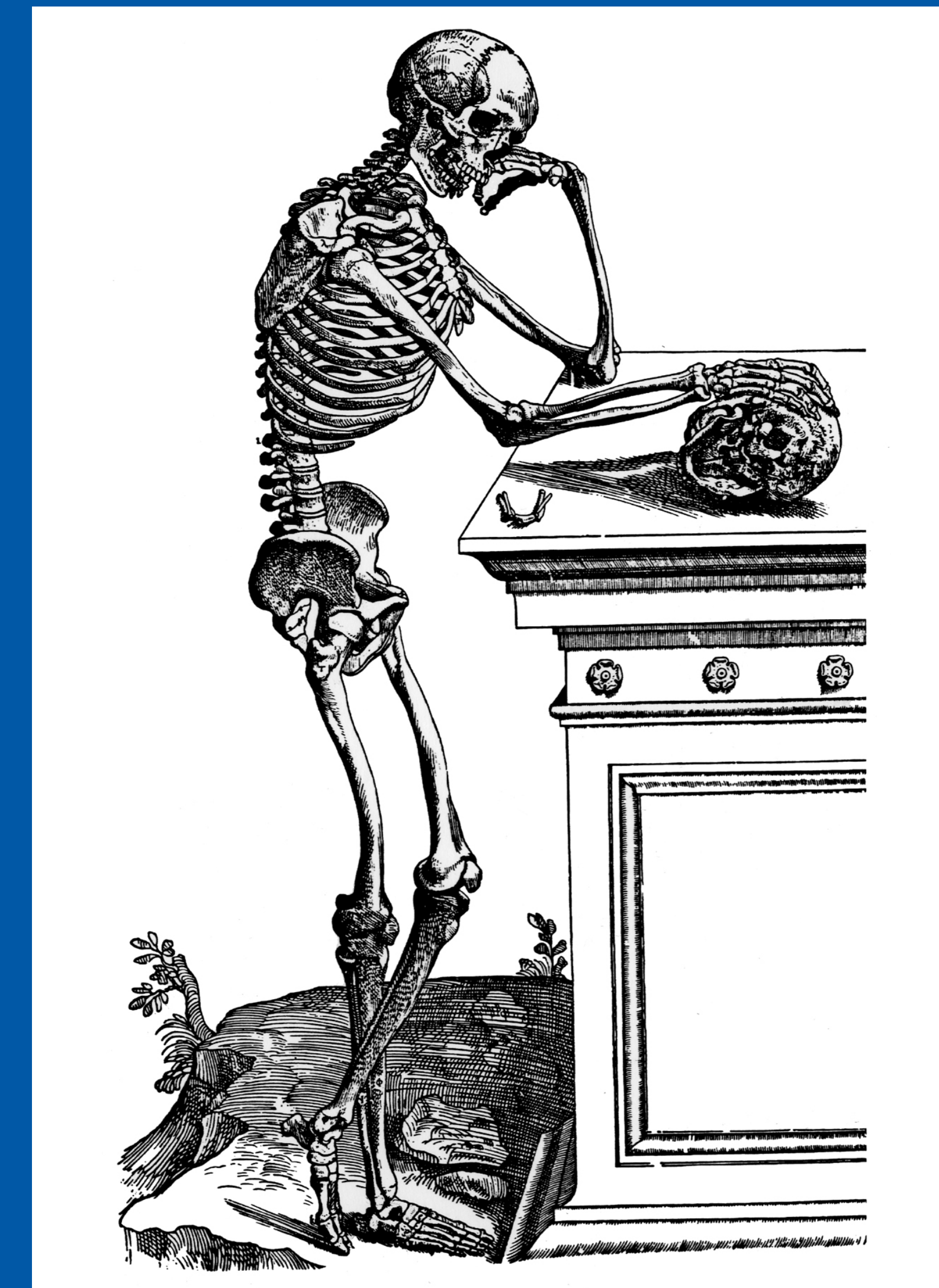


43rd Annual Meeting, Huntington Beach, California Society of Skeletal Radiology

March 29 - April 1, 2020

CASE OF THE DAY: SUNDAY

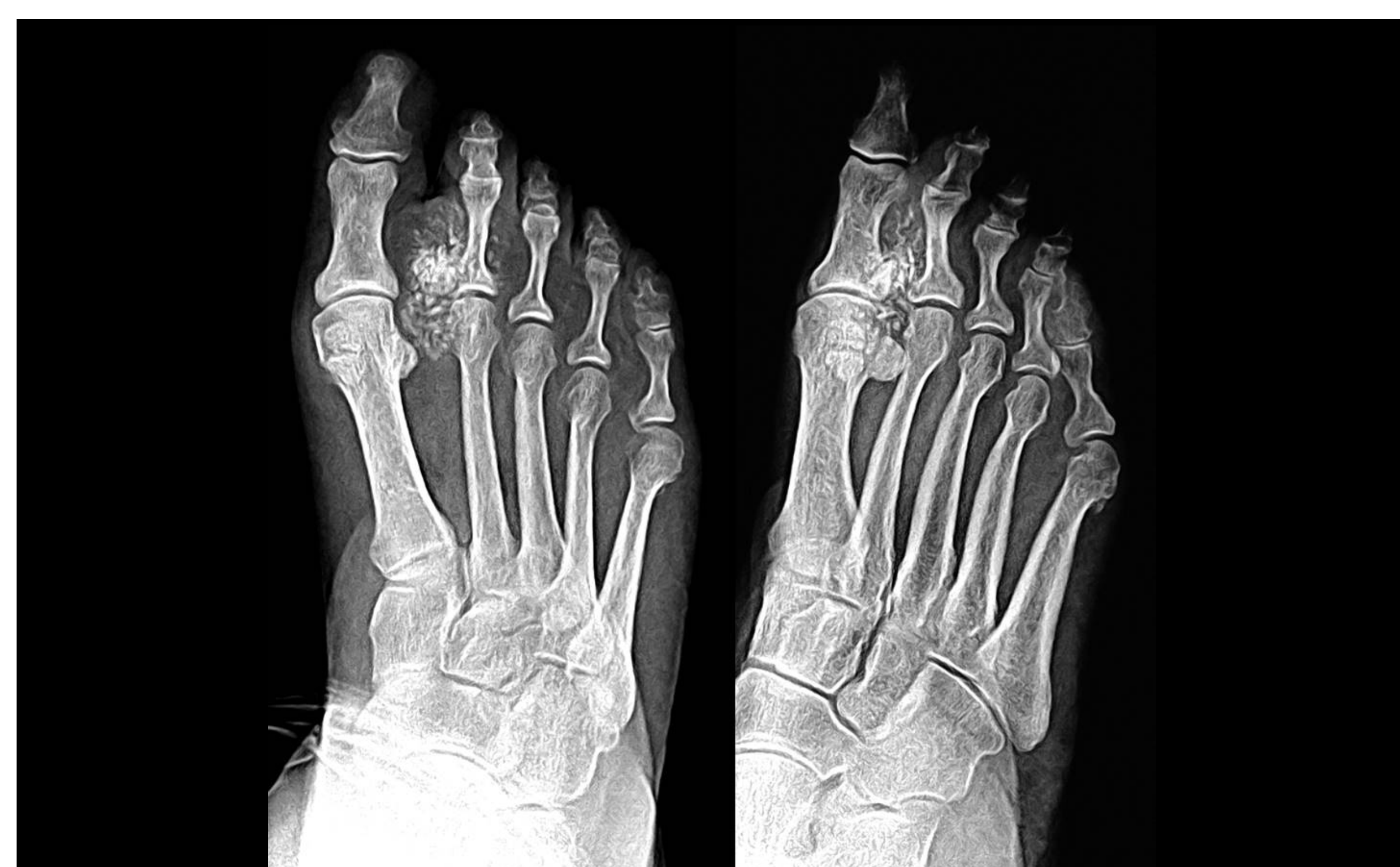 #SSRBONE20COD1



Chadwick Garner, MD; Hailey Allen, MD; Brian Chan, MD
University of Utah, Salt Lake City, UT

HISTORY

- 69-year-old woman
- Painful enlarging right second toe mass
- First noticed several years ago when it was the size of a pea



DIAGNOSIS

Ossifying Plexiform Tumor

- Extremely rare entity, with only 4 cases reported in the literature to date
- The descriptive name stems from the histologic appearance - lobules of epithelioid and spindled components arranged in a plexiform pattern separated by fibrous bands with bone formation in the center of the lobules
- All cases treated with total excision, with only one case of local recurrence
- No reported cases of metastasis
- Differential Diagnosis:
 - Cellular neurothekeoma
 - Fibro-osseous pseudotumor of the digits
 - Bizarre parosteal osteochondromatous proliferation
 - Ossifying fibromyxoid tumor of soft parts

