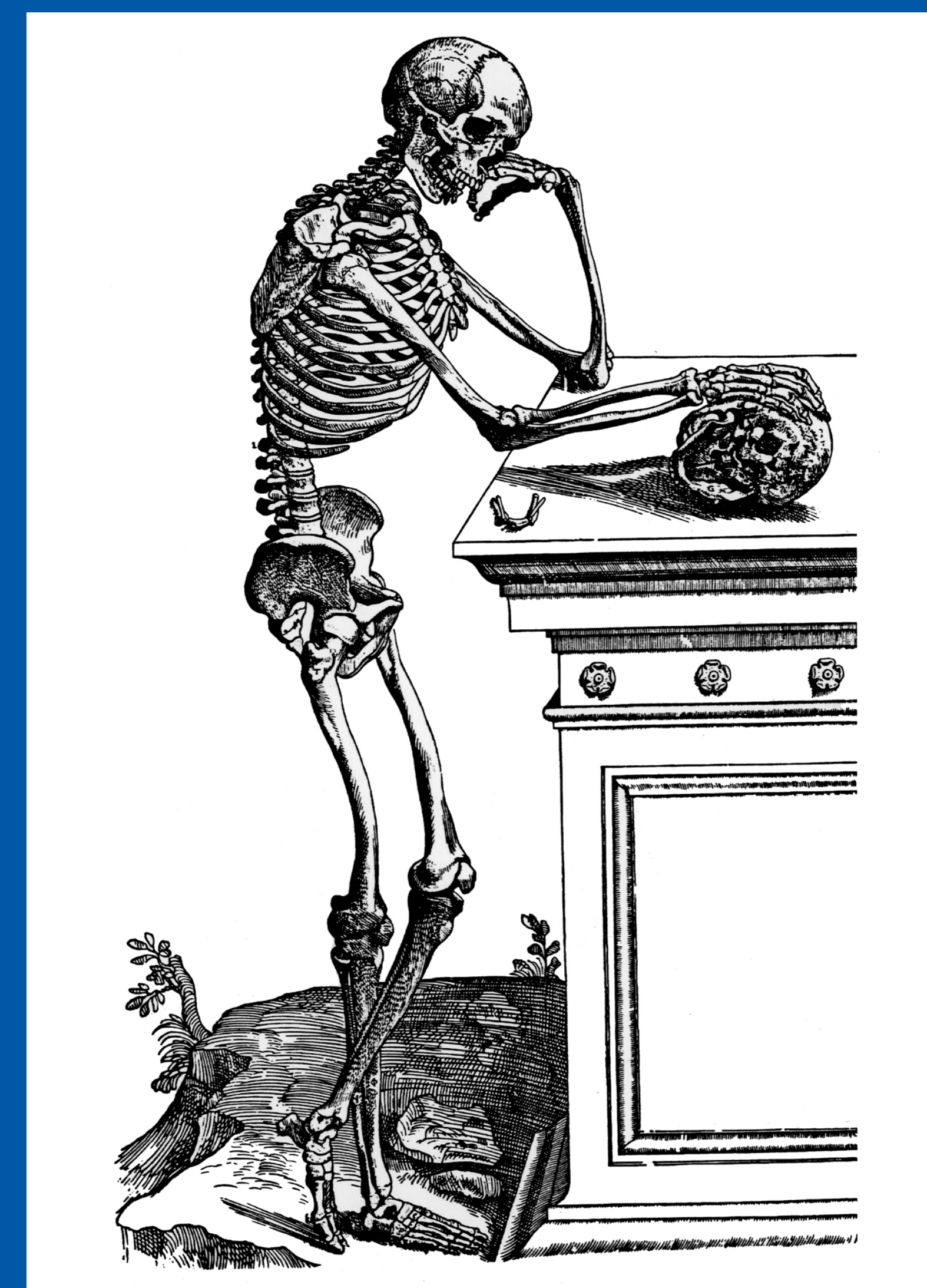


43rd Annual Meeting, Huntington Beach, California Society of Skeletal Radiology

March 29 - April 1, 2020

CASE OF THE DAY: MONDAY

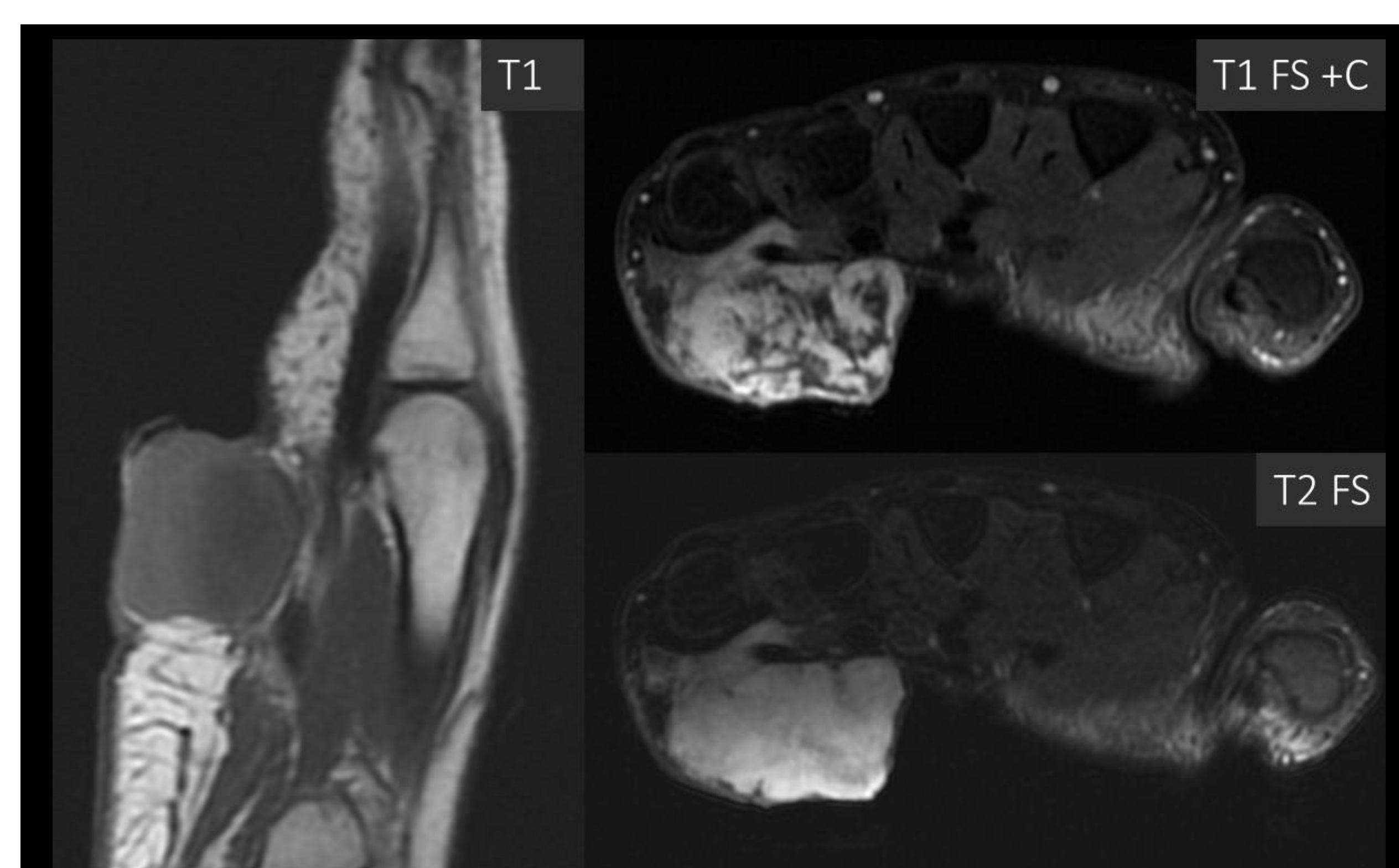
 #SSRBONE20COD3



Joseph Tang, MD; Kirkland W. Davis, MD; Darya Buehler, MD
University of Wisconsin School of Medicine and Public Health, Madison, WI

HISTORY

- 37-year-old man
- Rapidly growing (over six weeks) volar right hand mass
- No systemic or constitutional symptoms



DIAGNOSIS

Nodular Fasciitis

- Benign subcutaneous, fascial, or intramuscular tumor with clonal fibroblastic / myofibroblastic proliferation (recurrent MYH9 - USP6 gene fusion)
- Volar forearm (46%), head/neck (20%), trunk (18%), lower extremity (16%)
- MR appearance depends on composition – can be myxoid, cellular, fibrous, or a combination
- Fascial tail sign – suggests nodular fasciitis in the appropriate setting
- Can mimic sarcoma due to rapid growth, mitotic activity, high cellularity
- Can regress spontaneously, but often surgically resected with low recurrence rate

