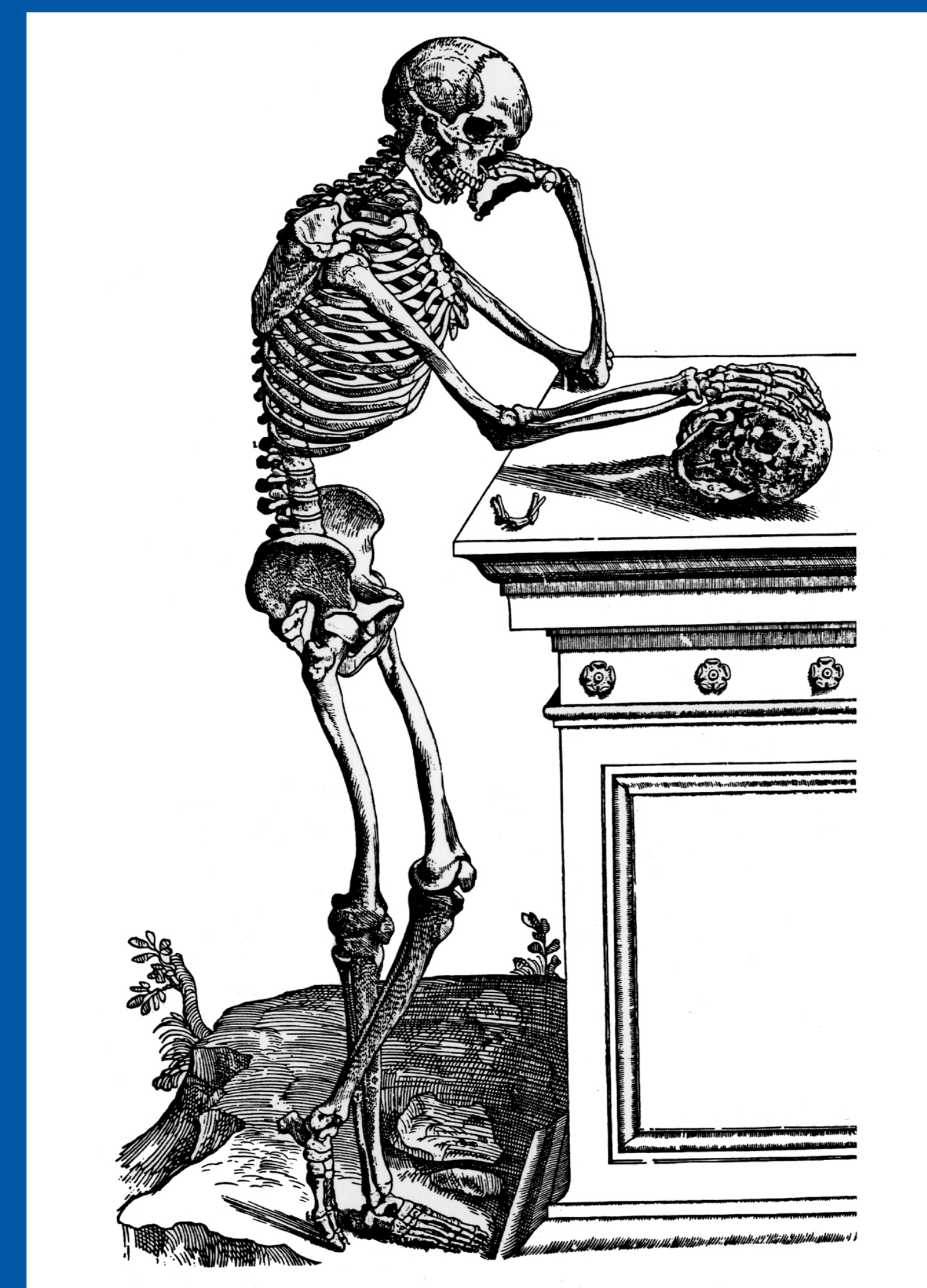


# 43rd Annual Meeting, Huntington Beach, California Society of Skeletal Radiology

March 29 - April 1, 2020

## CASE OF THE DAY: WEDNESDAY

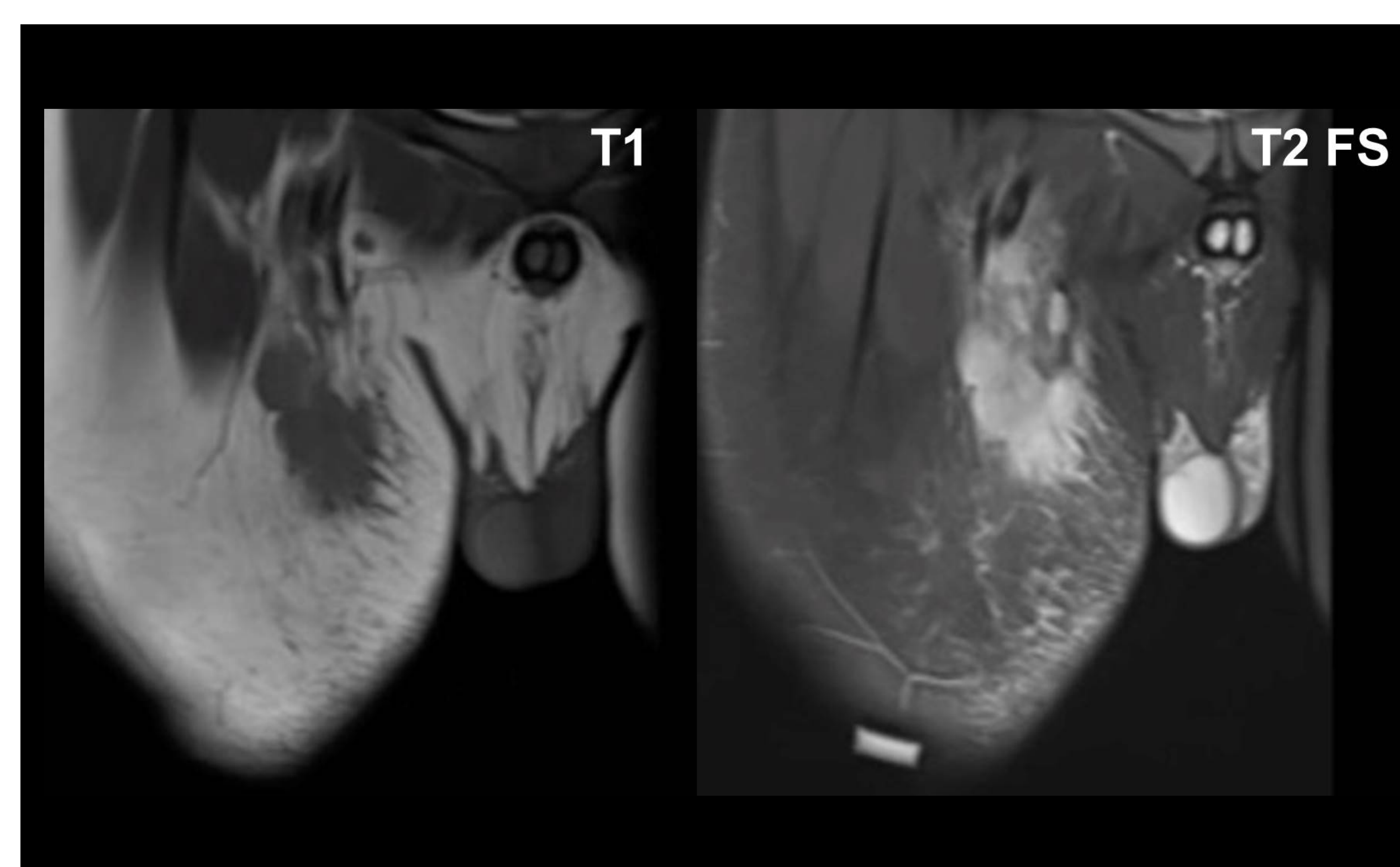
 #SSRBONE20COD7



Cassandra Parrott, DO; Peter Anderson, MD; Hakan Ilaslan, MD  
Cleveland Clinic, Cleveland, OH

### HISTORY

- 13-year-old male
- New palpable right inguinal mass
- Outside hospital biopsy was non-diagnostic
- Repeat biopsy is requested



### DIAGNOSIS

#### Cat Scratch Disease

- Benign subcutaneous, fascial, or intramuscular tumor with clonal fibroblastic / myofibroblastic proliferation (recurrent MYHP - USP6 gene fusion)
- Volar forearm (46%), head/neck (20%), trunk (18%), lower extremity (16%)
- MR appearance depends on composition – can be myxoid, cellular, fibrous, or a combination
- Fascial tail sign – suggests nodular fasciitis in the appropriate setting
- Can mimic sarcoma due to rapid growth, mitotic activity, high cellularity
- Can regress spontaneously, but often surgically resected with low recurrence rate

