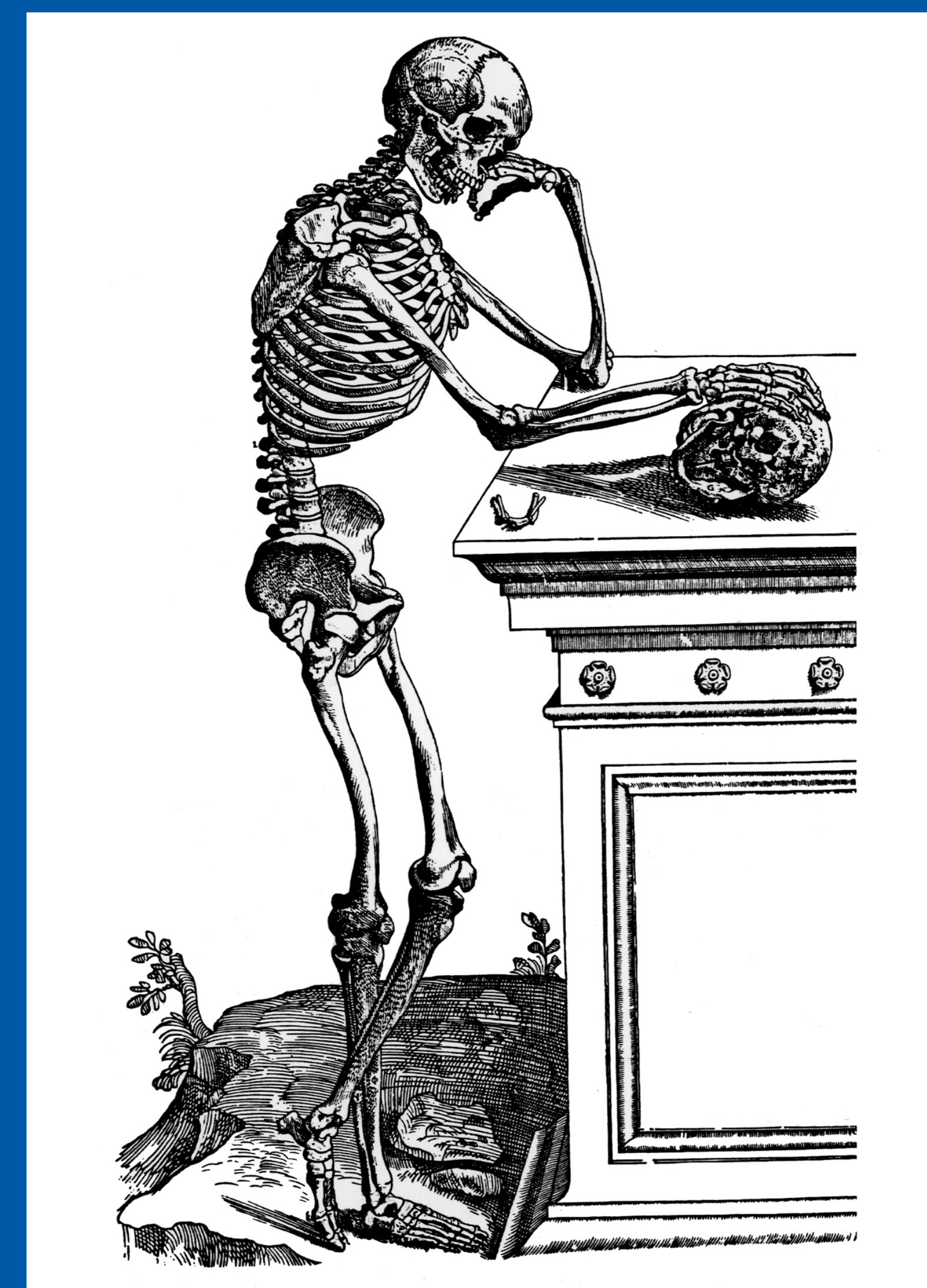


43rd Annual Meeting, Huntington Beach, California Society of Skeletal Radiology

March 29 - April 1, 2020

CASE OF THE DAY: MONDAY

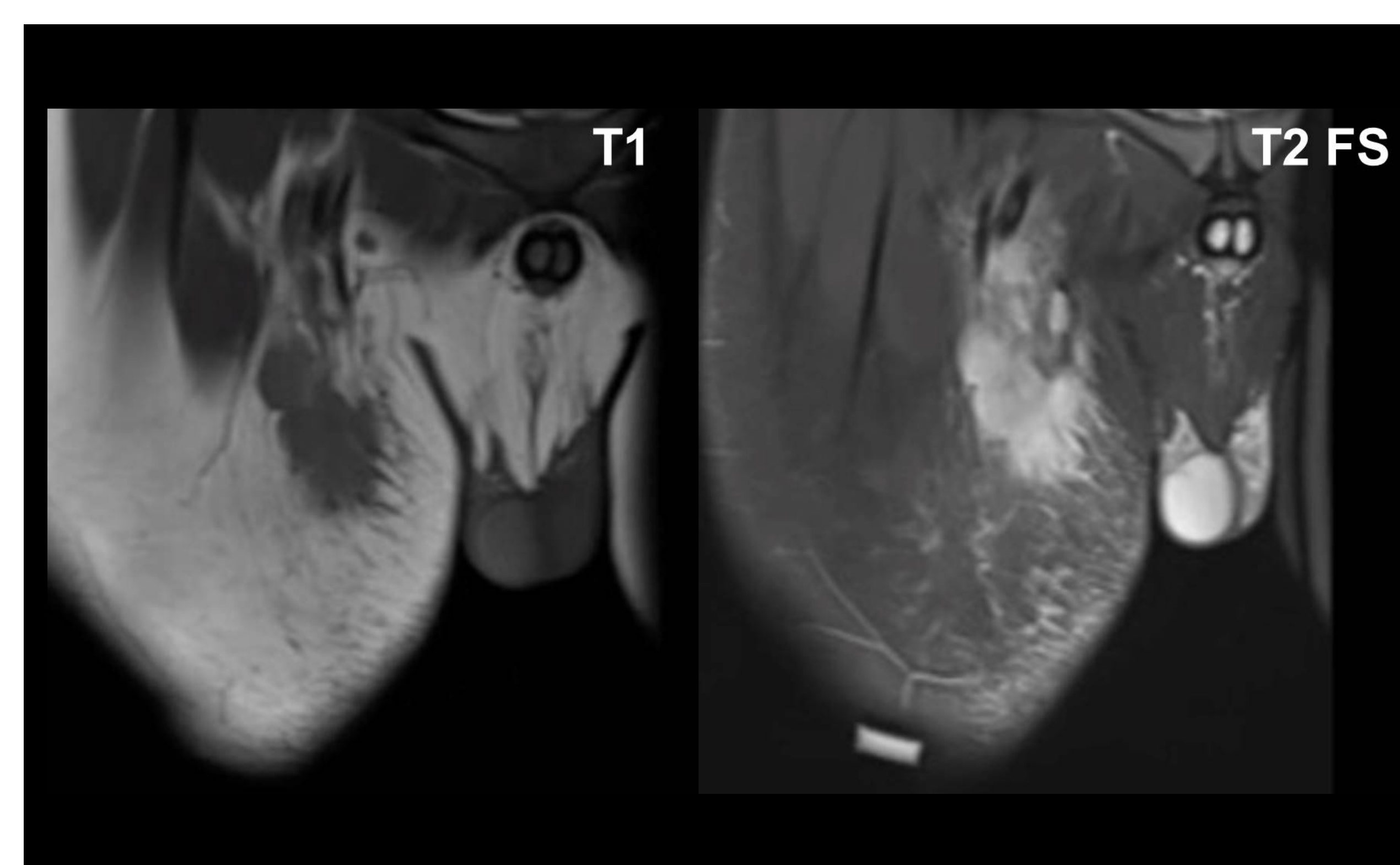
 #SSRBONE20COD7



Cassandra Parrott, DO; Peter Anderson, MD; Hakan Ilaslan, MD
Cleveland Clinic, Cleveland, OH

HISTORY

- 13-year-old male
- New palpable right inguinal mass
- Outside hospital biopsy was non-diagnostic
- Repeat biopsy is requested



DIAGNOSIS

Cat Scratch Disease

- *Bartonella henselae* infection with entry at site of cat scratch or bite
- Typical presentation is painful regional lymphadenopathy at or near entry point of infection
- Upper extremity more typical
- MR appearance:
 - increased signal intensity on fluid sensitive sequences
 - avid enhancement post contrast
 - surrounding soft tissue edema
- In this case:
 - lymphoma suspected at OSH prompted biopsy
 - Repeat biopsy canceled given classic appearance and conformation of new kitten in family

