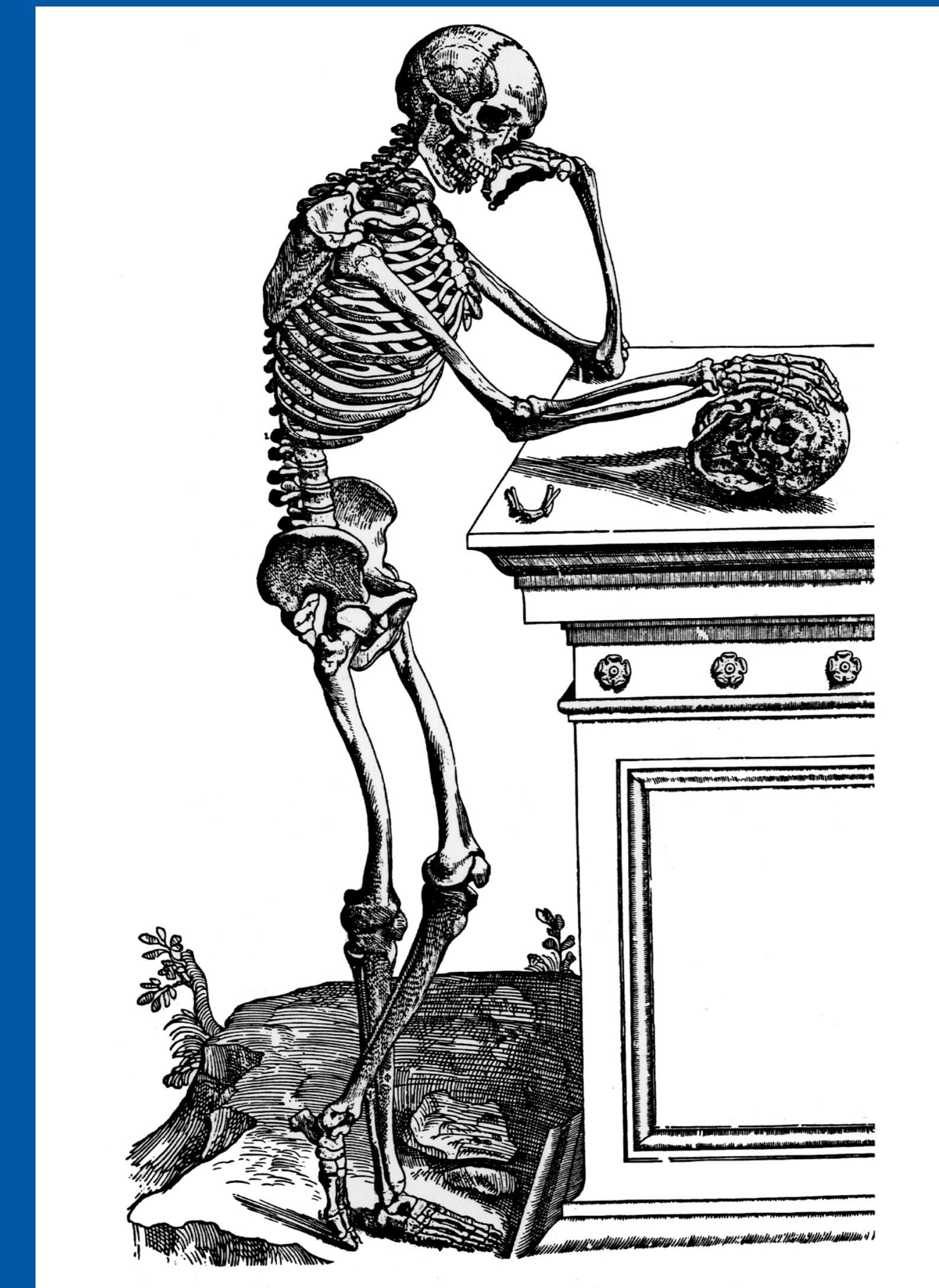


44th Annual Meeting
Society of Skeletal Radiology
March 13 - 17, 2021

CASE OF THE DAY: SUNDAY

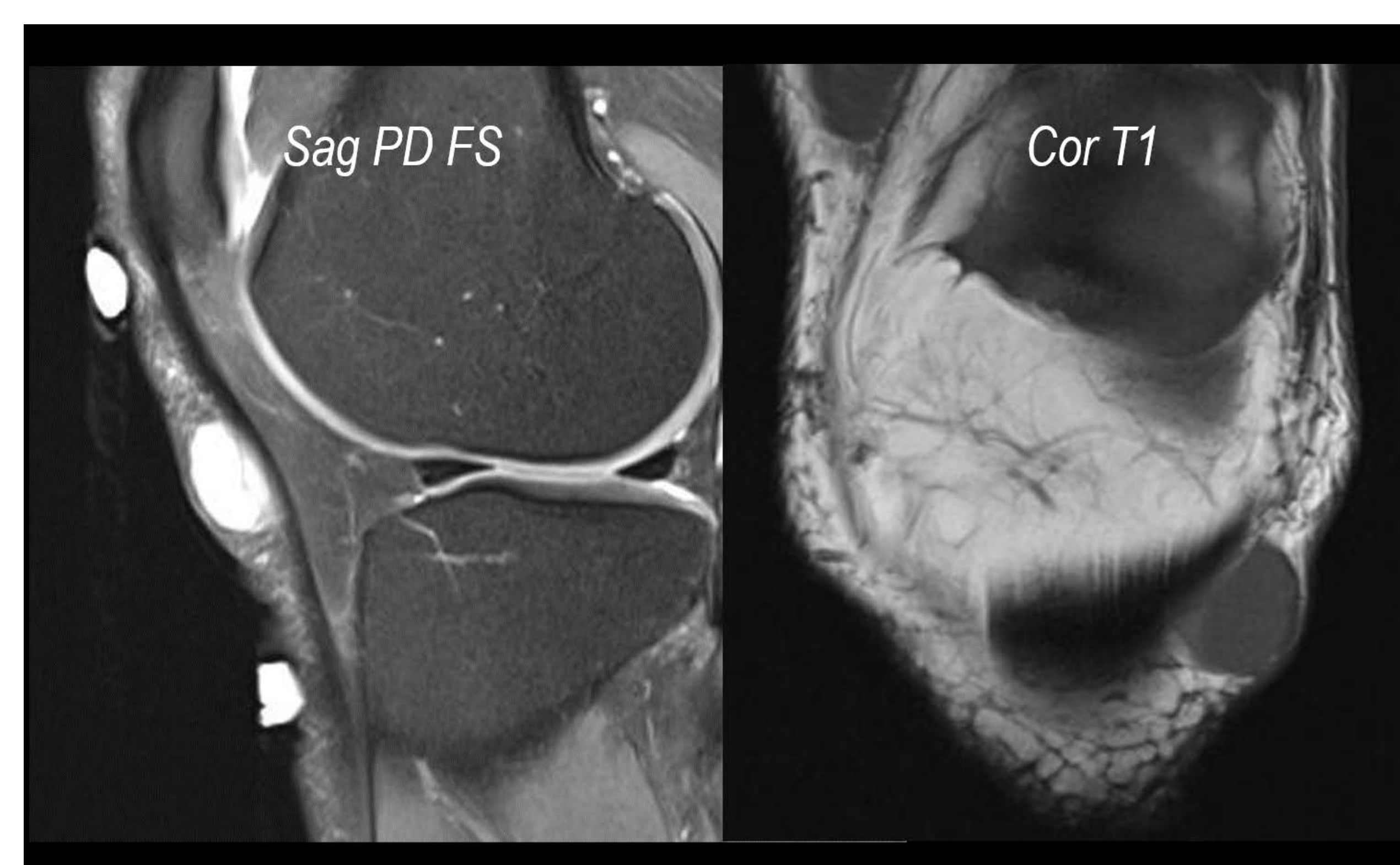
 #SSRBONE21COD1



Corey Hiti, MD; Mark Kransdorf, MD
Mayo Clinic, Scottsdale, AZ

HISTORY

- 60-year-old man
- Medical history
 - Diabetes
 - POEMS syndrome
- Palpable soft tissue mass
 - present for 12 years
 - recently doubled in size



DIAGNOSIS

Trichoblastoma

- Rare, benign skin entity with follicular differentiation
- Typically presents as a small nodule in hair bearing areas
- Most commonly in head or neck
- Rarely reported as a subcutaneous soft tissue mass
- Some subtypes may contain melanin pigmentation
- Must be distinguished pathologically from basal cell carcinoma and trichoblastic carcinoma

