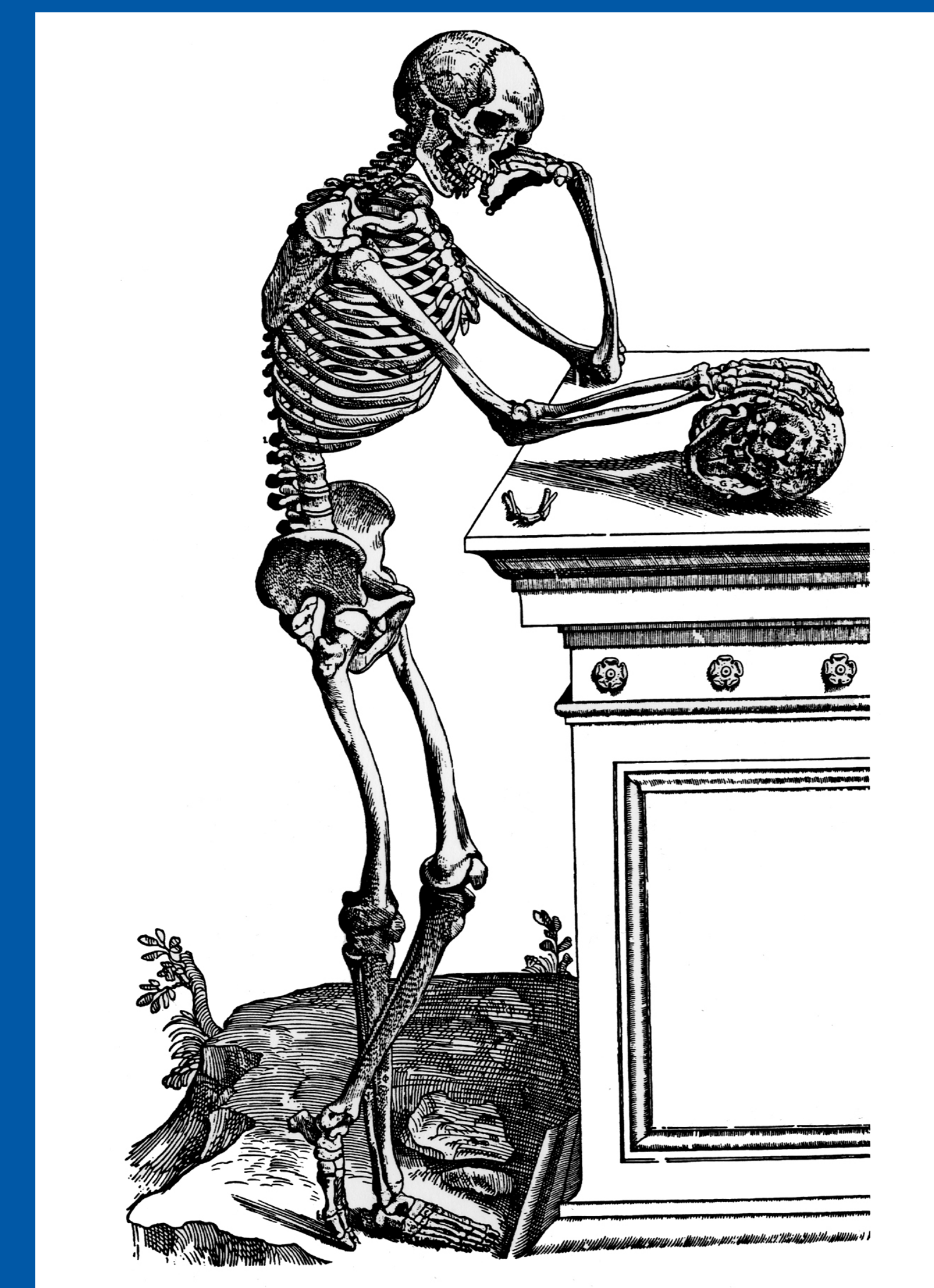


44th Annual Meeting  
Society of Skeletal Radiology  
March 13 - 17, 2021

# CASE OF THE DAY: SUNDAY

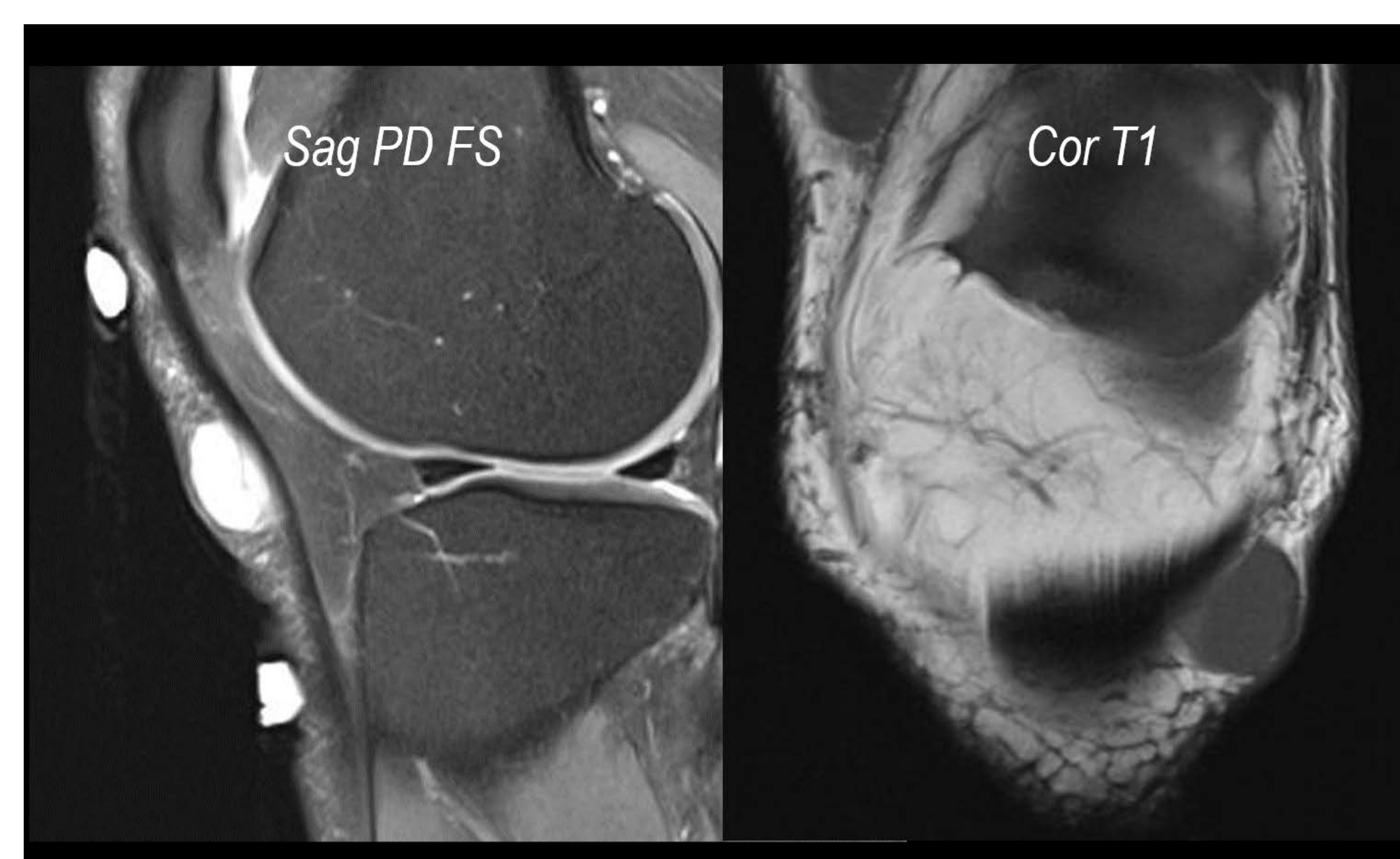
 #SSRBONE21COD1



Corey Hiti, MD; Mark Kransdorf, MD  
Mayo Clinic, Scottsdale, AZ

## HISTORY

- 60-year-old man
- Medical history
  - Diabetes
  - POEMS syndrome
- Palpable soft tissue mass
  - present for 12 years
  - recently doubled in size



## DIAGNOSIS

