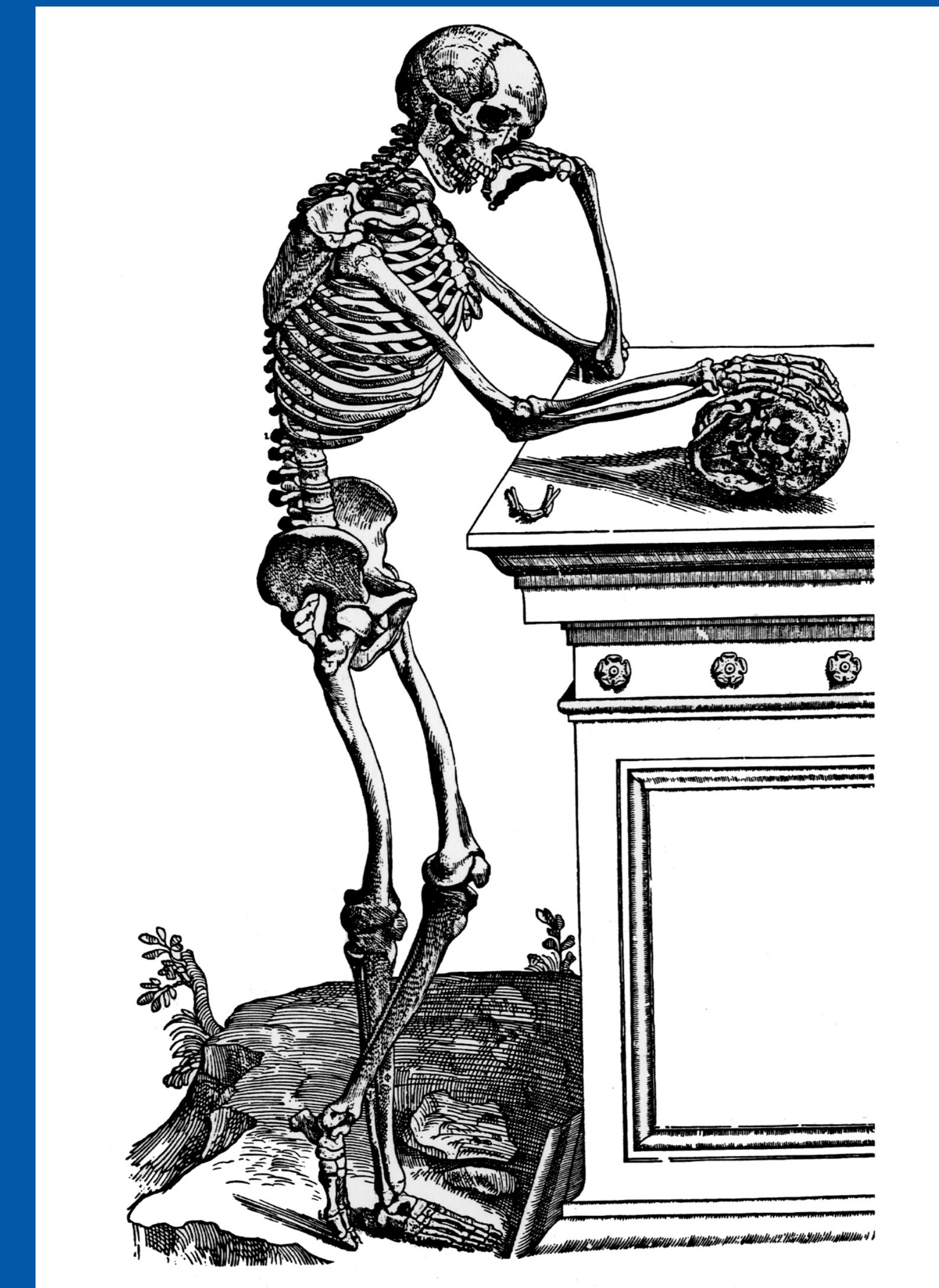


44th Annual Meeting
Society of Skeletal Radiology
March 13 - 17, 2021

CASE OF THE DAY: SUNDAY

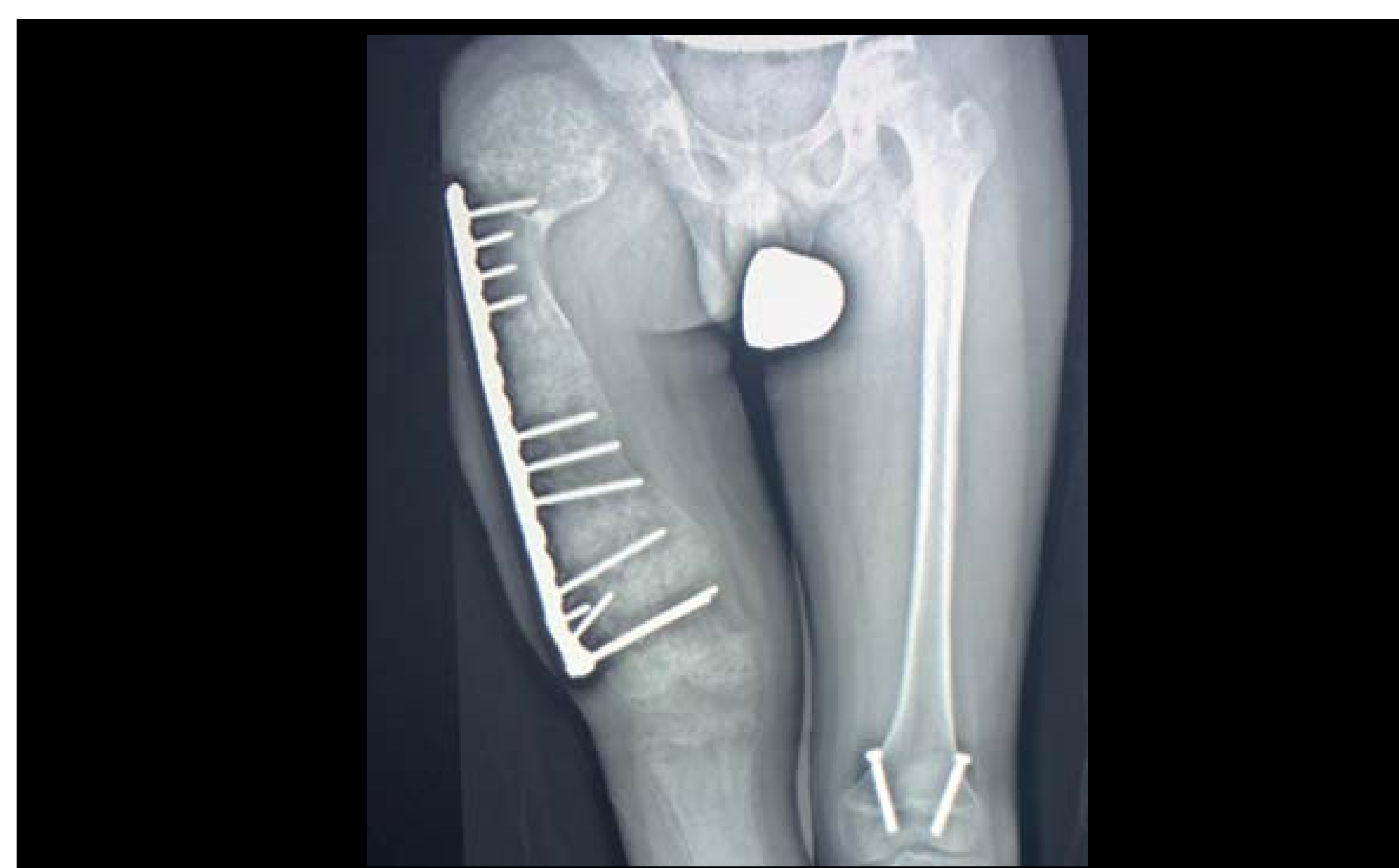
 #SSRBONE21COD2



Barry Hansford, MD; Jessica Davis, MD; Melanie Hakar, DO
Oregon Health & Sciences University, Portland, OR

HISTORY

- 13-year-old male
- Long standing right leg pain
- Limb length discrepancy and deformity



DIAGNOSIS

Polyostotic Cartilagenous Fibrous Dysplasia

- Rare variant of fibrous dysplasia
- Radiology
 - "Groundglass" appearance typical of fibrous dysplasia, plus
 - "Arcs and rings" of calcification typical of cartilage forming lesions
- Pathology
 - Cartilage with high cell density throughout
 - Typical fibrous dysplasia findings less prominent
- Differential Diagnosis
 - Enchondromatoses
 - McCune-Albright or Mazabraud syndrome
 - Malignant degeneration of fibrous dysplasia

