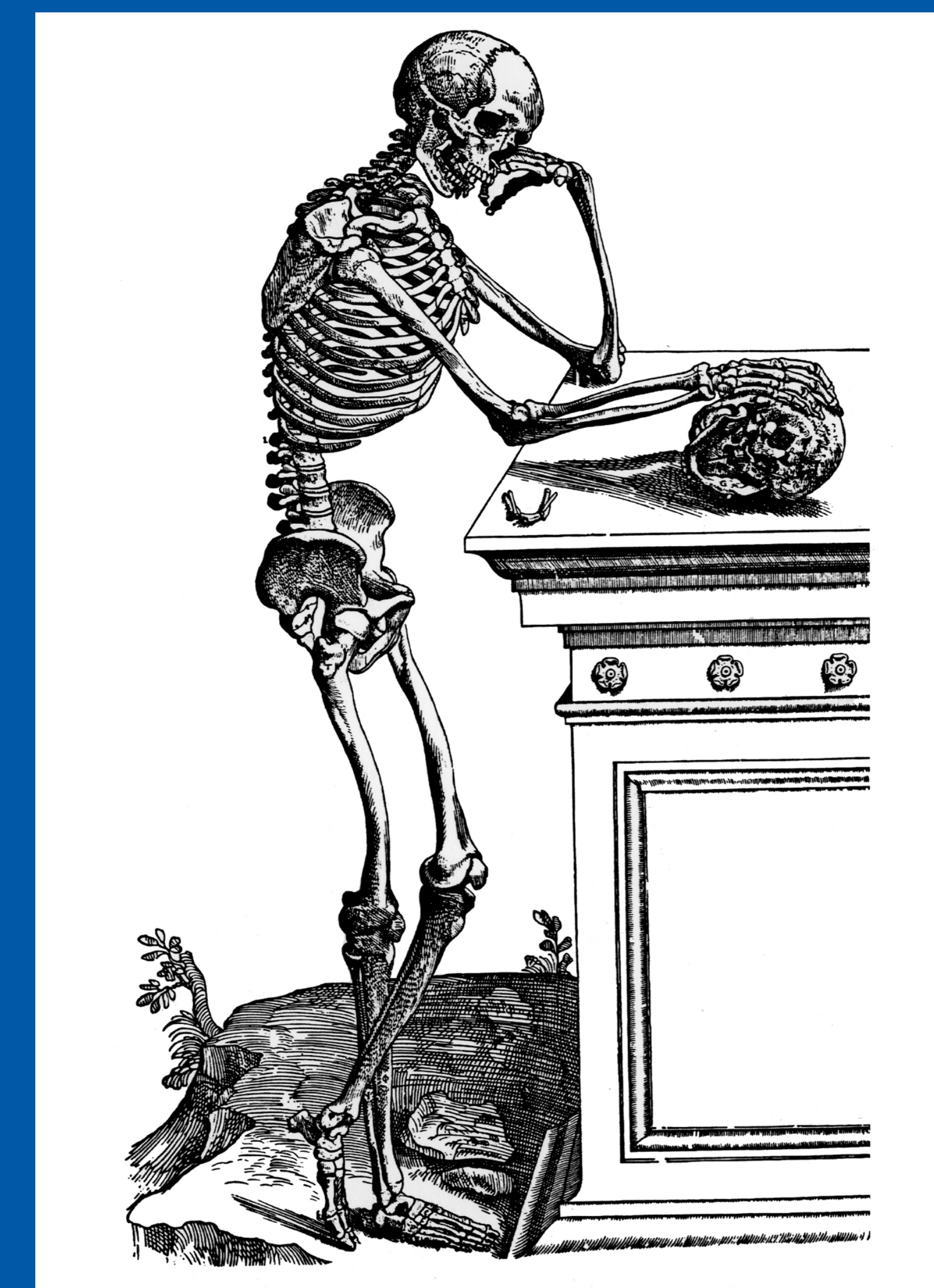


44th Annual Meeting  
Society of Skeletal Radiology  
March 13 - 17, 2021

# CASE OF THE DAY: SUNDAY

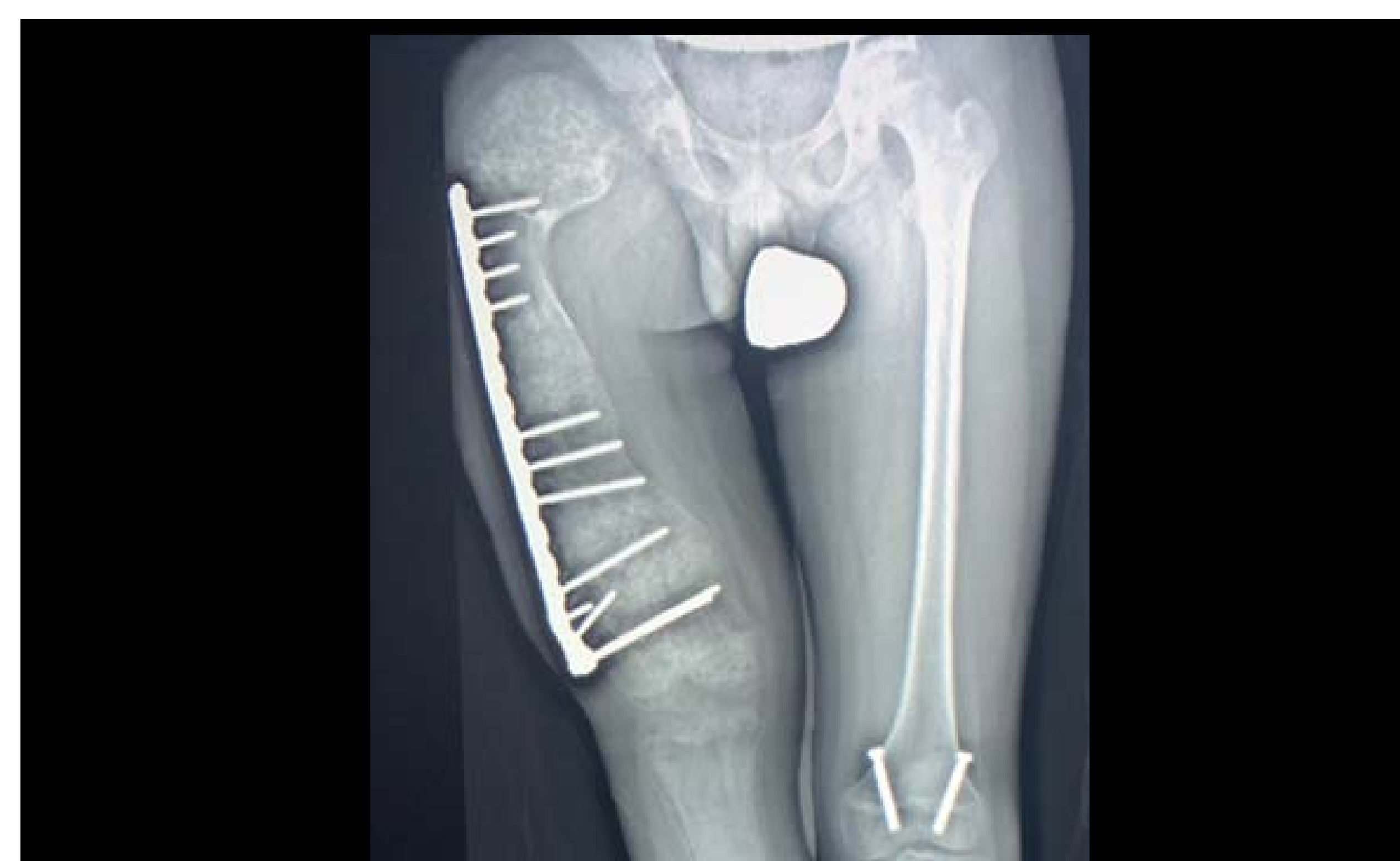 #SSRBONE21COD2



Barry Hansford, MD; Jessica Davis, MD; Melanie Hakar, DO  
Oregon Health & Sciences University, Portland, OR

## HISTORY

- 13-year-old male
- Long standing right leg pain
- Limb length discrepancy and deformity



## DIAGNOSIS

