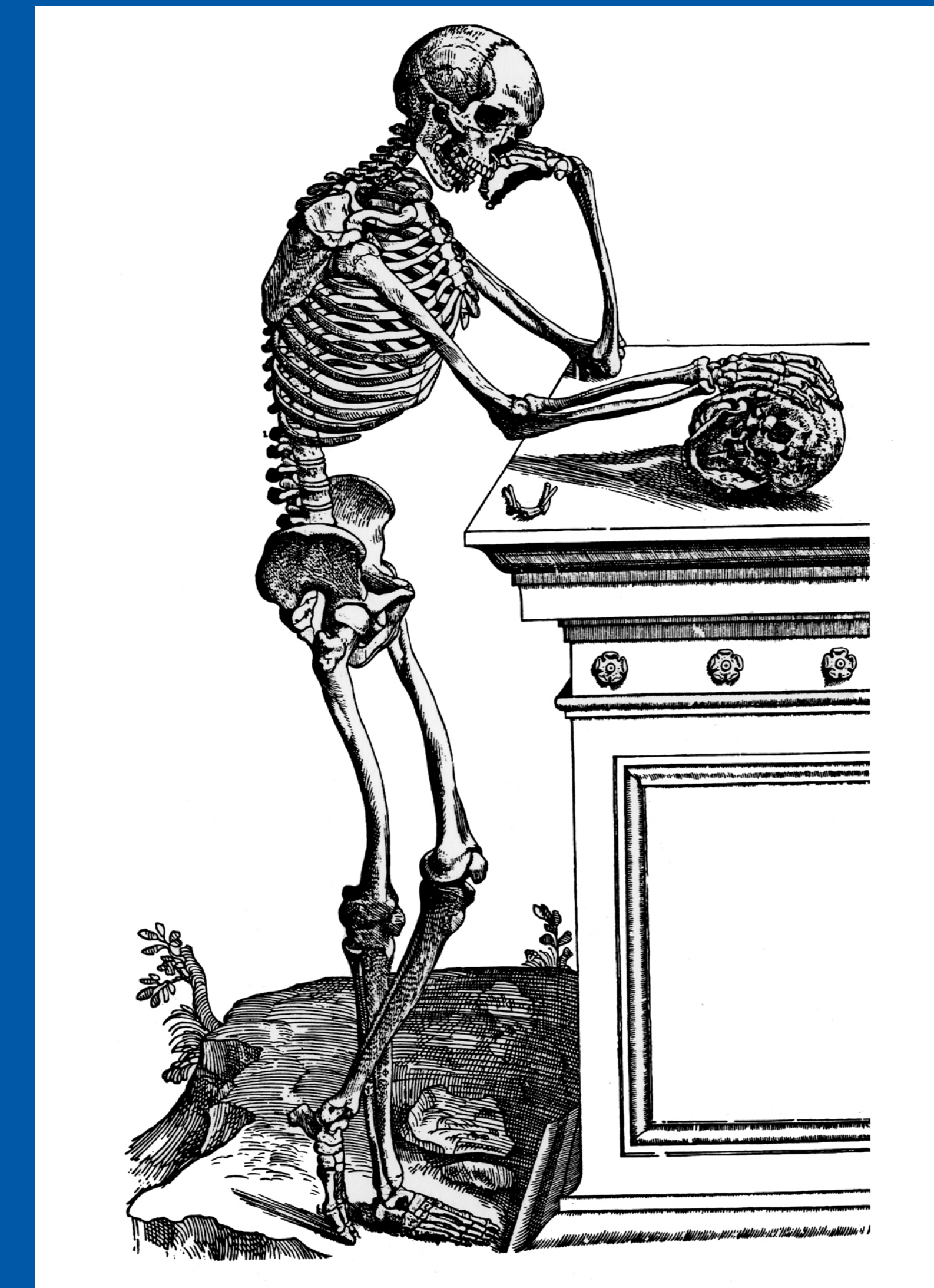


44th Annual Meeting Society of Skeletal Radiology

March 13 - 17, 2021

CASE OF THE DAY: MONDAY

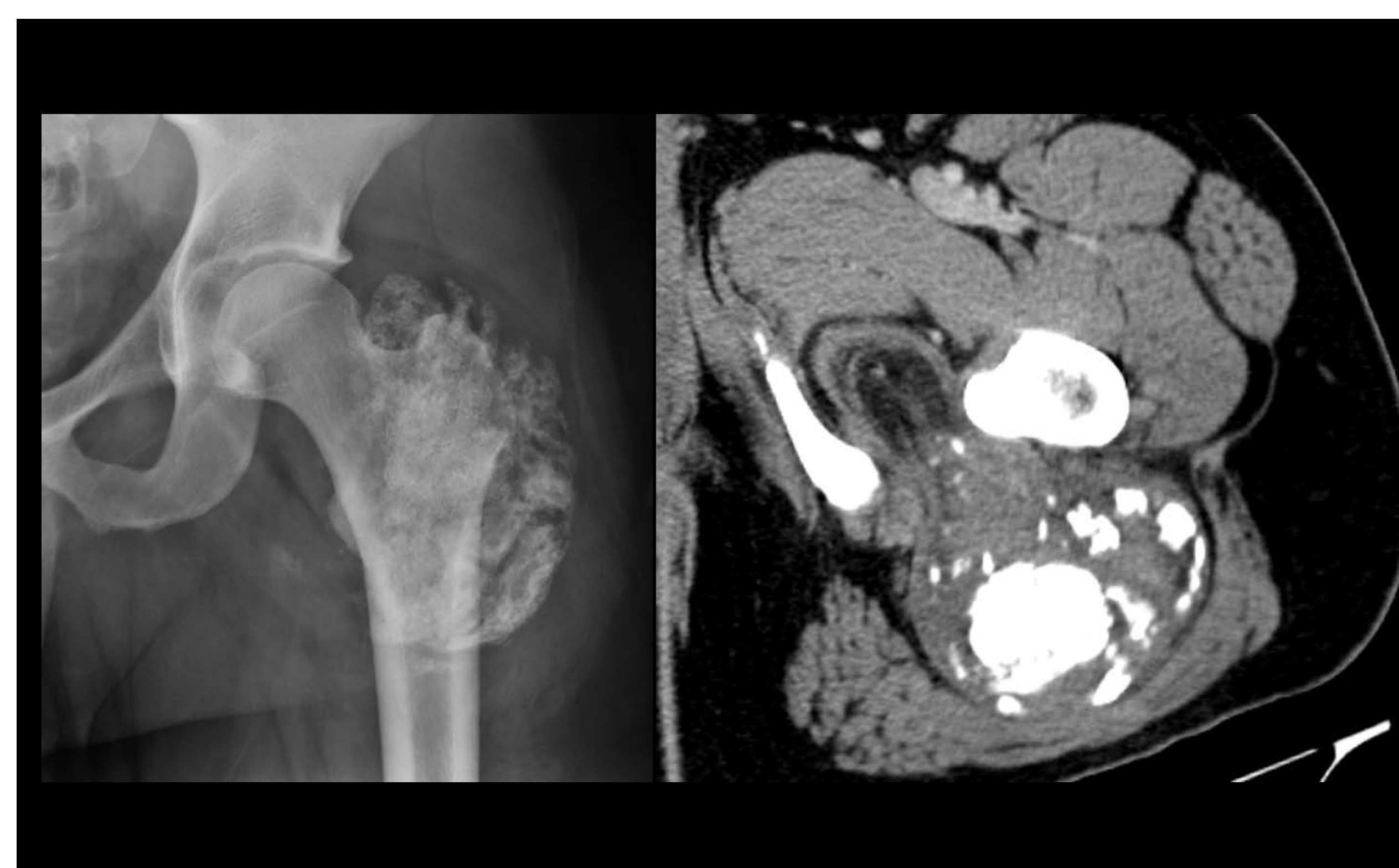 #SSRBONE21COD4



John Symanski, MD; Reena Singh, MD; Rajeev Mannem, MD
Medical College of Wisconsin, Milwaukee, WI

HISTORY

- 32-year-old male with 3 years of generalized hip pain
- Left foot numbness with prolonged sitting
- Fell on left buttock 8 years prior with resultant bruising



DIAGNOSIS

Ossifying Lipoma (Osteolipoma)

- Rarest lipoma subtype
 - mature adipose tissue and trabecular bone
 - +/- calcified chondroid matrix and fat necrosis with dystrophic calcifications
- Pathogenesis is unclear
 - tumor arising from multipotent mesenchymal cells?
 - ossification due to repetitive trauma or inflammatory process?
- Imaging - lipomatous lesion with ossification
- Principle imaging differential diagnosis is liposarcoma
- Pathology - variable amounts of adipose tissue, lamellar bone and cartilage

